Journal of Anatomy

J. Anat. (2019) **234**, pp346–358 doi: 10.1111/joa.12924

Physiological *in vitro* sacroiliac joint motion: a study on three-dimensional posterior pelvic ring kinematics

Niels Hammer,[1,2,3] Mario Scholze,[1,4] Thomas Kibsgård,[5] Stefan Klima,[2,6] Stefan Schleifenbaum,[2] Thomas Seidel,[7] Michael Werner[3,8] and Ronny Grunert[3,9]

[1]*Department of Anatomy, University of Otago, Dunedin, New Zealand*
[2]*Department of Orthopedic and Trauma Surgery, University Clinics of Leipzig, Germany*
[3]*Fraunhofer Institute for Machine Tools and Forming Technology IWU, Dresden, Germany*
[4]*Institute of Materials Science and Engineering, Chemnitz University of Technology, Chemnitz, Germany*
[5]*Department of Orthopedics, Oslo University Hospital, Oslo, Norway*
[6]*Orthopaedicus Clinics, Leipzig, Germany*
[7]*Institute of Cellular and Molecular Physiology, Friedrich-Alexander University Erlangen-Nürnberg (FAU), Erlangen, Germany*
[8]*Department of Anatomy, University of Leipzig, Germany*
[9]*Department of Neurosurgery, University of Leipzig, Leipzig, Germany*

Abstract

The sacroiliac joint (SIJ) is a well-known source of low back and pelvic pain, of increasing interest for both conservative and surgical treatment. Alterations in the kinematics of the pelvis have been hypothesized as a major cause of SIJ-related pain. However, definitions of both the range and the extent of physiological movement are controversial, and there are no clear baseline data for pathological alterations. The present study combined a novel biomechanical setup allowing for physiological motion of the lumbosacral transition and pelvis without restricting the SIJ movement *in vitro*, combined with optical image correlation. Six fresh human pelvises (81 ± 10 years, three females, three males) were tested, with bodyweight-adapted loading applied to the fifth lumbar vertebra and both acetabula. Deformation at the lumbopelvises was determined computationally from three-dimensional image correlation data. Sacroiliac joint motion under the loading of 100% bodyweight primarily consisted of a *z*-axis rotation (0.16°) and an inferior translation of the sacrum relative to the ilium (0.32 mm). Sacroiliac joint flexion-extension rotations were minute (< 0.02°). Corresponding movements of the SIJ were found at the lumbosacral transition, with an anterior translation of L5 relative to the sacrum of −0.97 mm and an inferior translation of 0.11 mm, respectively. Moreover, a flexion of 1.82° was observed at the lumbosacral transition. Within the innominate bone and at the pubic symphysis, small complementary rotations were seen around a vertical axis, accounting for −0.10° and 0.11°, respectively. Other motions were minute and accompanied by large interindividual variation. The present study provides evidence of different SIJ motions than reported previously when exerted by physiological loading. Sacroiliac joint kinematics were in the sub-degree and sub-millimeter range, in line with previous *in vivo* and *in vitro* findings, largely limited to the sagittal rotation and an inferior translation of the sacrum relative to the ilium. This given physiological loading scenario underlines the relevance of the lumbosacral transition when considering the overall motion of the lumbopelvis, and how relatively little the other segments contribute to overall motion.

Key words: digital image correlation; innominate bone motion; nutation; pelvic girdle pain; pubic symphysis; sacroiliac joint kinematics.

Introduction

The sacroiliac joint (SIJ) is known to be both a site of load transmission between the spine and lower extremities, and an important contributor to low back and posterior pelvic girdle pain (Schwarzer et al. 1995; Robert et al. 1998; Fortin et al. 1999; Cohen, 2005; Forst et al. 2006; Szadek et al. 2009; Laplante et al. 2012; Cohen et al. 2013; Visser et al. 2013). In recent years, a number of non-surgical (Dussault

Correspondence
Niels Hammer, Department of Anatomy, University of Otago, Lindo Ferguson Building, 270 Great King St, Dunedin 9016, New Zealand.
T: + 64 3 4797362, *F*: + 64 3 4797254; *E*: *nlshammer@googlemail.com*

Accepted for publication *15 November 2018*
Article published online *9 December 2018*

et al. 2000; Damen et al. 2002; Fritz et al. 2008; Jee et al. 2014; Kasliwal & Kasliwal, 2016; Kurosawa et al. 2016) and surgical techniques (Waisbrod et al. 1987; Buchowski et al. 2005; Al-Khayer et al. 2008; Khurana et al. 2009; Ebraheim et al. 2010; Biswas et al. 2016; Duhon et al. 2016) have evolved for its treatment. A particular aim is to relieve nerve irritation related to SIJ pathology (Kibsgård et al. 2014a) or to reduce SIJ motion by means of surgical implants (Kube & Muir, 2016). One underlying assumption for these therapies is that they influence SIJ pain as a consequence of altering motion. Sound scientific evidence of such alterations is still pending, and there is conflicting data for reference values of physiological movement (Weisl, 1955; Lavignolle et al. 1983; Jacob & Kissling, 1995; Kissling & Jacob, 1996; Sturesson et al. 1999, 2000a; Kibsgård et al. 2012, 2014b; Egund & Jurik, 2014).

The movement of the SIJ, the so-called nutation, has been described to consist mainly of flexion-extension rotation (medial-lateral axis) and an anterior-inferior translation of the sacrum relative to the ilium (Kapandji, 2009) in the direction of the lesser pelvis. Though a number of qualitative data exist on SIJ nutation (Weisl, 1955; Kissling et al. 1990; Kissling & Jacob, 1996; Kapandji, 2009), the lack of methods to assess deformation accurately, hampers quantification. Studies on SIJ motion vary largely, comparing *in vivo* (Lavignolle et al. 1983; Sturesson et al. 1999, 2000a, b; Kibsgård et al. 2014a) to *in vitro* (Frigerio et al. 1974; Vleeming et al. 1989, 1992b; Simonian et al. 1994b; Miller & Routt, 2012) and numeric (Ivanov et al. 2009; Sichting et al. 2014) approaches. Moreover, previous clinical studies used bone markers and were largely limited to one or two axes (Frigerio et al. 1974; Egund et al. 1978; Lavignolle et al. 1983; Kissling et al. 1990; Jacob & Kissling, 1995; Kissling & Jacob, 1996; Sturesson et al. 2000a) or planes (Fessler, 1894; Weisl, 1955). The resulting measurement uncertainty of the SIJ impacts on what can be defined a physiological range of movement, especially *in vitro*, and if SIJ pathology is at all related to increased or decreased overall motion.

Another important consideration in SIJ biomechanics is the involvement of kinematic chains (Vleeming et al. 1996). The SIJ is not an isolated joint at the posterior pelvis. Both SIJs work conjointly with the pubic symphysis joint in a horizontal chain of motion segments. Additionally, the sacrum with both adjacent SIJs forms a second, vertical chain, situated between the lumbosacral transition and the hip joints, embedded in a number of muscles that act as active stabilizers (Panjabi, 1992a,b). This complex interplay maintains both form and force closure at the pelvis, but makes it impossible to examine the SIJ independently, as the overall motion is multi-segmental. Previous studies limiting this multi-segmental motion may therefore lack in interpretability (Simonian et al. 1994b; Wang & Dumas, 1998; Bruna-Rosso, 2014; Lindsey et al. 2014).

The aim of the present study was to establish and trial a novel biomechanical setup to examine the *in vitro* SIJ deformation as a part of the human pelvic ring. The setup included a physiological load application via the fifth lumbar vertebra (L5) and both hip joints using spherical stamp components, allowing for a similar load distribution as *in vivo*. It was hypothesized that motion in the SIJ would be markedly smaller than reported previously and in line with our recent finite elements study (Sichting et al. 2014).

This kinematic study confirmed consistent but minute SIJ nutation movements under physiological loading, mainly consisting of a translation of the ilium relative to the sacrum in the coronal plane. Moreover, a second rotation was observed about the *z*-axis. The experiments have also provided strong evidence towards the lumbosacral transition being a major contributor to lumbopelvic mobility, with movements outnumbering the other movements at the pelvic ring. These kinematic findings provide new insights into load distribution in the posterior pelvis, potentially with an impact on contemporary treatment strategies.

Materials and methods

Preparation of the human tissues

The given experiments were carried out with six human cadaveric lumbopelvises (mean age 81.3 ± 10.0 years, range 65–96 years; Table 1). Being part of the body donor program was regulated by the Saxonian Death and Funeral Act of 1994, and institutional approval for the use of the postmortem tissues of human body donors was obtained from the Institute of Anatomy, University of Leipzig. The authors declare that all experiments have been conducted according to the principles of the Declaration of Helsinki. Inclusion criteria of the tissues were a postmortem delay of 48 h or less and the absence of cancer or chronic diseases with potential impact onto the musculoskeletal system. All tissues were processed in a fresh condition to exclude alterations in the mechanical properties of the bones (Hammer et al. 2014) and the ligaments (Steinke et al. 2012). The pelvises were retrieved in a similar manner as described previously (Steinke et al. 2014; Höch et al. 2017), and gross removal of soft tissues was carried out quickly to minimize autolysis. The resulting pelvises included the innominate bones, the sacrum and L5 vertebra with all adjacent ligaments remaining intact. Metal pins were inserted into the L5 and reinforced by means of RENCAST FC52 Isocyanate/FC52 Polyol/Ceramic Powder (RenShape solutions, Huntsman International LLC, Salt Lake City, UT, USA). The metal pins served as a mount for an indentation plate to be linked with the material testing machine. Additionally, adjustable titanium plates were mounted onto the iliac crest bilaterally and fixed with AO standard screws of individual lengths to fit into the iliac bones.

Mechanical testing and optical image correlation

A double-leg stance setup was used to apply loads via L5 with a uniaxial material testing machine (DYNA-MESS, Aachen, Germany). Steel wires mounted to the titanium plates at the iliac crest were used to simulate muscle traction of the erector spinae and the abdominal wall muscles. Load application was carried

out in a physiological manner via a spherical stamp component connected to the material testing machine. Match-sized femoral head components were used to mount both acetabula to the bottom plates of the testing machine (Fig. 1). Preconditioning (20 cycles, 100 N s^{-1}) was performed with a load range varying between 0 N and 20% of the individual's bodyweight. The load-deformation tests were carried out with 100% of the donors' bodyweight in 12 cycles with a constant velocity of 150 N s^{-1}. In a final cycle, each pelvis was loaded until failure. Synchronous digital optical image correlation (DIC) data were recorded (Limess, Krefeld, Germany) with 2.0 megapixels at 5 fps (Schleifenbaum et al. 2016). For this purpose, speckle patterns were added at predefined locations of the pelvis, including L5, the sacral promontory, sacral and iliac alae, iliac wings and the superior pubic rami. The testing duration depended on the maximum force applied to the pelvises, capturing 1400–2400 images for each pelvis. The precision of the three-dimensional movement recording was 0.01 pixel, or 1 μm. Using the DIC software (Istra4D, Dantec, Skovlunde, Denmark), movements of the following sites were exported:

- Sacroiliac joint: sacral ala relative to iliac ala, bilaterally
- Lumbosacral transition: L5 relative to sacrum,
- Innominate bone – superior pubic ramus versus iliac ala, bilaterally, pubis relative to ilium
- Pubic symphysis: right relative to left superior pubic ramus

Data evaluation

A MATLAB routine (version 2017a, MathWorks, Inc., Natick, MA, USA) was used to import the coordinates of marked triangle points together with the corresponding displacements corrected for rigid body movement at each time step (rigid body motion removed, RBMR). The raw data was first noise-filtered over time by a moving mean filter with a centered window spanning 25 steps. For each triangle, the center of mass (C = centroid) was calculated. The relative displacement s_{rel} of a triangle A with respect to a second triangle B was defined as the difference in centroid displacements:

$$s_{\mathrm{rel}} = \Delta\mathrm{CA} - \Delta\mathrm{CB} = (x_{C,A} - x_{C,B}, y_{C,A} - y_{C,B}, z_{C,A} - z_{C,B})$$

The resulting displacements were used to compute load- and bodyweight-dependent displacements as RBMR functions for the SIJ, the lumbosacral transition, the innominate bones and the pubic symphysis. Additionally, for each pair of triangles A and B, rotation of B around the centroid of A was calculated. For this purpose, the center of the Cartesian coordinate system was identified with the centroid of A. The points of B were then registered for each time step to step 0 using the iterative closest point (ICP) algorithm implemented in MATLAB (pcregrigid). The transformation matrix was decomposed to obtain rotations around the x-, y- and z-axes. The axes have been defined as follows: x-axis – medial-lateral, y-axis – inferior-superior, z-axis – posterior anterior (Fig. 1), and Euler angles were reported. Both translations and rotations were solved from the rotation matrix in the order Z-Y-X.

The deformation curves were then scanned and evaluated via a second MATLAB routine. Movements of the corresponding regions were retrieved from the 12 load cycles. Load cycles were evaluated as relative changes at a preload (50 N) = 0, 20, 40, 60, 80 and 100% of the cadavers' bodyweight and as absolute changes at a preload (50 N), 100 N, 200 N, 300 N, 400 N and 500 N. To prevent influences of setting phenomena in the deformation data, each individual load cycle was referenced to the previous preloaded (50 N-) step, allowing for an offset correction. Means and standard deviations were calculated from the sampled points for every single region.

The minimum threshold for motions of the pelvis to be recognized was 0.1-mm translation, or 0.1° rotation, between 0 and 100% of the bodyweight.

Statistical analyses

Data processing and statistical comparisons were carried out using Microsoft Excel version 16.12 (Redmond, WA, USA) and Prism (GraphPad Software, Inc., La Jolla, CA, USA).

Table 1 Characteristics of the donor tissues and the mechanical setup.

Number	Sex	Age (years)	Body weight (kg)	Cause of death	Pelvis mass (g)	Preconditioning (N)	Load testing (N)	Ultimate failure load (N)	Failure site
69–13	Male	81	87	Mesenterial infarction	2656	256	853	2495	L5 fracture
71–13	Female	81	56	Acute renal failure	1495	165	549	1941	SIJ dislocation
101–14	Female	96	67	Pneumonia	2464	197	657	1650	Sacral fracture
121–14	Male	75	56	Malignant neoplasm of the stomach	1889	165	549	4500	SIJ dislocation
03–15	Male	65	98	Malignant neoplasm of the biliary duct	2744	288	961	2700	SIJ dislocation
11–15	Female	90	78	Chronic hypertrophic heart failure	2116	230	765	1941	SIJ dislocation
Mean ± SD		81.3 ± 10.0	73.7 ± 15.6					2537.8 ± 946.8	

SIJ, sacroiliac joint.
The weight of the pelvis was considered when calculating preconditioning and testing loads.

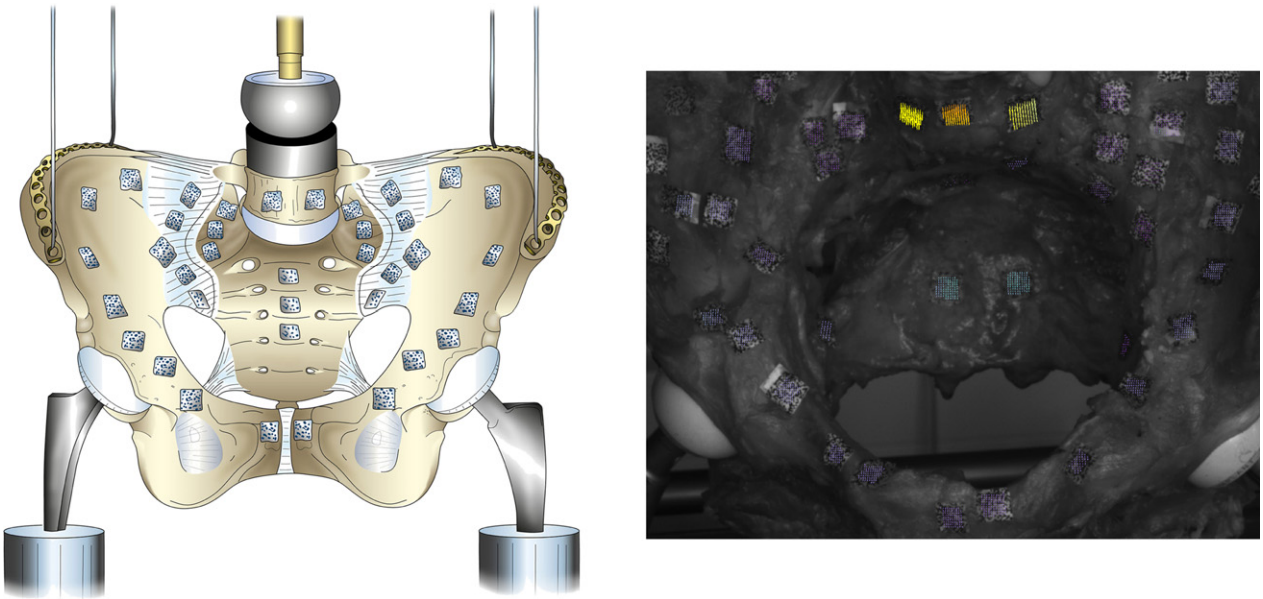

Figure 1 Experimental setup for physiological load application. The left image summarizes the overall setup and the right image is an example of motion patterns of L5 (yellow patterns) relative to the pelvis (pink patterns) during digital image correlation.

Results

The six pelvises completed the preconditioning and the 12 cycles in the described loading scenarios without demonstrating signs of premature mechanical failure and were included in the further evaluations. The mean failure load was 2538 ± 947 N (range 1650–4500 N; Table 1). Results from the absolute loading comparison (0–500 N) yielded similar translations and rotations relative to the bodyweight (Table 2, Supporting Information Tables S1 and S2). The accuracy of each motion is given in Supporting Information Table S3. Movements at 60% bodyweight or loads < 500 N were consistently lower than at 100% bodyweight or 500 N, respectively. The following considerations are therefore based on 100% bodyweight. Movements of the SIJs and the innominate bones were averaged from both sides, movements of the lumbosacral transition are given for L5 relative to S1, and movements of the pubic symphysis are given for the comparison of right relative to left.

The movement in double-leg stance in the SIJ combines a *z*-axis rotation of the ilium with an inferior (*y*-) translation of the sacrum

When the femoral load was changed from zero to 100% of the bodyweight there were small rotations detected in the *z*-axis of the SIJ with an average of $R_z = 0.16 \pm 0.13°$ (mean ± SD), with the iliac crest innominate bone moving inwards to the cranial aspect of the sacrum (Fig. 2A, Supporting Information Figure S1A). The translation in the *y*-direction averaged $T_y = 0.32 \pm 0.31$ mm, causing the innominate bone to move cranially relative to the sacrum (or, vice versa, the sacrum to move inferiorly). Increased loading consistently resulted in increased movement.

Movement at the lumbosacral transition in double-leg stance: (*x*-axis) flexion rotation combined with an inferior (*y*-) and anterior (*z*-) translation of L5

The rotation between the L5 and the sacrum in the *x*-axis was $R_x = 1.82 \pm 1.04°$, an L5 flexion movement, the largest rotation of all segments of the lumbosacral transition and pelvis (Figs 2B and S1B). Translations were observed in the *y*-direction with $T_y = -0.97 \pm 0.55$ mm and in the *z*-direction with $T_z = 0.11 \pm 0.46$ mm, respectively; as a consequence of the rotation of the anterior aspect of L5 relative to the sacral promontory, this caused the anterior L5-S1 disk space to narrow. Increased loading consistently resulted in increased deformation.

Motion within the innominate bone and pubic symphysis: minute *y*-axis rotation

The dominating rotation within the innominate bone was $R_y = -0.10 \pm 0.08°$, causing the pubic bone to rotate medially relative to the posterior pelvis (Figs 2C and S1C). Similar observations were made at the pubic symphysis, $R_y = -0.11 \pm 0.05°$ (Figs 2D and S1D), continuous with the innominate bone rotation. These movements were, however, on the verge of measurement accuracy (Table S3). Though consistent increases in the other rotations and

Table 2 Movements of the sacroiliac joint, the lumbosacral transition (L5–sacrum), within the innominate bone and at the pubic symphysis under 60% and 100% bodyweight.

			Translation (mm)			Rotation (°)		
Load (% BW)			*x*	*y*	*z*	*x*	*y*	*z*
Sacroiliac joint	60	Mean	0.01 ± 0.02	**0.17 ± 0.19**	0.03 ± 0.03	0.01 ± 0.03	−0.01 ± 0.02	**0.08 ± 0.07**
		Min	−0.01	**0.01**	−0.02	−0.03	−0.04	**0.01**
		Max	0.05	**0.61**	0.07	0.09	0.05	**0.27**
	100	Mean	0.01 ± 0.04	**0.32 ± 0.31**	0.05 ± 0.06	0.01 ± 0.05	−0.02 ± 0.06	**0.16 ± 0.13**
		Min	−0.04	**0.01**	−0.03	−0.03	−0.11	**0.02**
		Max	0.09	**1.04**	0.15	0.13	0.10	**0.50**
L5– sacrum	60	Mean	0.00 ± 0.03	**−0.51 ± 0.32**	**0.07 ± 0.27**	**0.97 ± 0.62**	−0.01 ± 0.02	−0.06 ± 0.18
		Min	−0.06	**−0.92**	**−0.14**	**0.18**	−0.04	−0.41
		Max	0.05	**−0.16**	**0.63**	**1.78**	0.02	0.18
	100	Mean	0.00 ± 0.05	**−0.97 ± 0.55**	**0.11 ± 0.46**	**1.82 ± 1.04**	0.00 ± 0.04	−0.09 ± 0.33
		Min	−0.08	**−1.81**	**−0.25**	**0.34**	−0.06	−0.71
		Max	0.09	**−0.29**	**1.07**	**3.36**	0.07	0.37
Innominate bone	60	Mean	0.02 ± 0.02	0.04 ± 0.06	0.02 ± 0.04	−0.03 ± 0.05	**−0.05 ± 0.05**	0.00 ± 0.02
		Min	0.00	−0.01	−0.02	−0.13	**−0.15**	−0.03
		Max	0.06	0.18	0.11	0.04	**0.02**	0.05
	100	Mean	0.03 ± 0.03	0.07 ± 0.11	0.04 ± 0.08	−0.05 ± 0.09	**−0.10 ± 0.08**	−0.01 ± 0.05
		Min	0.00	−0.03	−0.06	−0.23	**−0.27**	−0.08
		Max	0.10	0.31	0.17	0.07	**0.03**	0.08
Pubic symphysis	60	Mean	0.04 ± 0.06	−0.02 ± 0.06	0.01 ± 0.02	−0.03 ± 0.04	**−0.06 ± 0.03**	−0.01 ± 0.02
		Min	−0.01	−0.15	−0.01	−0.13	**−0.10**	−0.03
		Max	0.15	0.04	0.05	0.01	**0.00**	0.02
	100	Mean	0.07 ± 0.10	−0.04 ± 0.11	0.02 ± 0.03	−0.05 ± 0.08	**−0.11 ± 0.05**	−0.01 ± 0.04
		Min	−0.02	−0.27	−0.01	−0.22	**−0.18**	−0.08
		Max	0.27	0.07	0.08	0.02	**−0.03**	0.03

Max, maximum; Min, minimum.
Clearly identifiable movements are highlighted in bold.

translations were observed as the result of increased loading, these changes were minute – below the threshold defining a movement – and were accompanied by large variation.

Discussion

A number of studies have made attempts to describe SIJ movements both qualitatively and quantitatively (Weisl, 1955; Egund et al. 1978; Lavignolle et al. 1983; Miller et al. 1987; Rothkötter & Berner, 1988; Sturesson et al. 1989, 1999, 2000a,b; Vleeming et al. 1989, 1992a,b; Simonian et al. 1994a; Jacob & Kissling, 1995; Kissling & Jacob, 1996; Wang & Dumas, 1998; Kibsgård et al. 2012, 2014b; Lindsey et al. 2014). The common observation is that its overall movement is multi-dimensional and held within a small range, but to a highly variable extent among individuals. The complex anatomy of the SIJ forms an important part of the reasons behind the variability in movements, with the characteristics of synovial and syndesmotic joints (Le Blanche et al. 1996; Forst et al. 2006). The restricted movement is known to be the consequence of bone and cartilage geometry, dense ligaments and muscles, combining the posterior pelvis under the principles of force and form closure (Panjabi, 1992a,b; Arumugam et al. 2012; Vleeming et al. 2012). The given *in vitro* experiments have shown that the SIJ moves to a relatively small overall extent, consisting of a sub-degree rotation in the anterior-posterior (*z*-) axis and a sub-millimeter inferior (*y*−) translation. The global movement at the pelvis corresponded to the local movements at the SIJ, the lumbosacral transition, the innominate bone and the pubic symphysis. Whereas the rotations at the SIJ were small and mostly limited to the sagittal axis, major flexion-extension rotations were found at the lumbosacral transition, accompanied by an anterior-inferior translation of L5 relative to the sacrum. Both the innominate bone and the pubic symphysis moved multi-dimensionally, but to a varying (minute) extent, and predominantly around vertical axes. A particular finding was that the movements in the lumbosacral transition outweighed all of the other rotations and translations, underlining the relevance of this segment in load distribution. Failure loads of the given experiments were in line with the experiments of Rothkötter & Berner (1988) in younger cadavers.

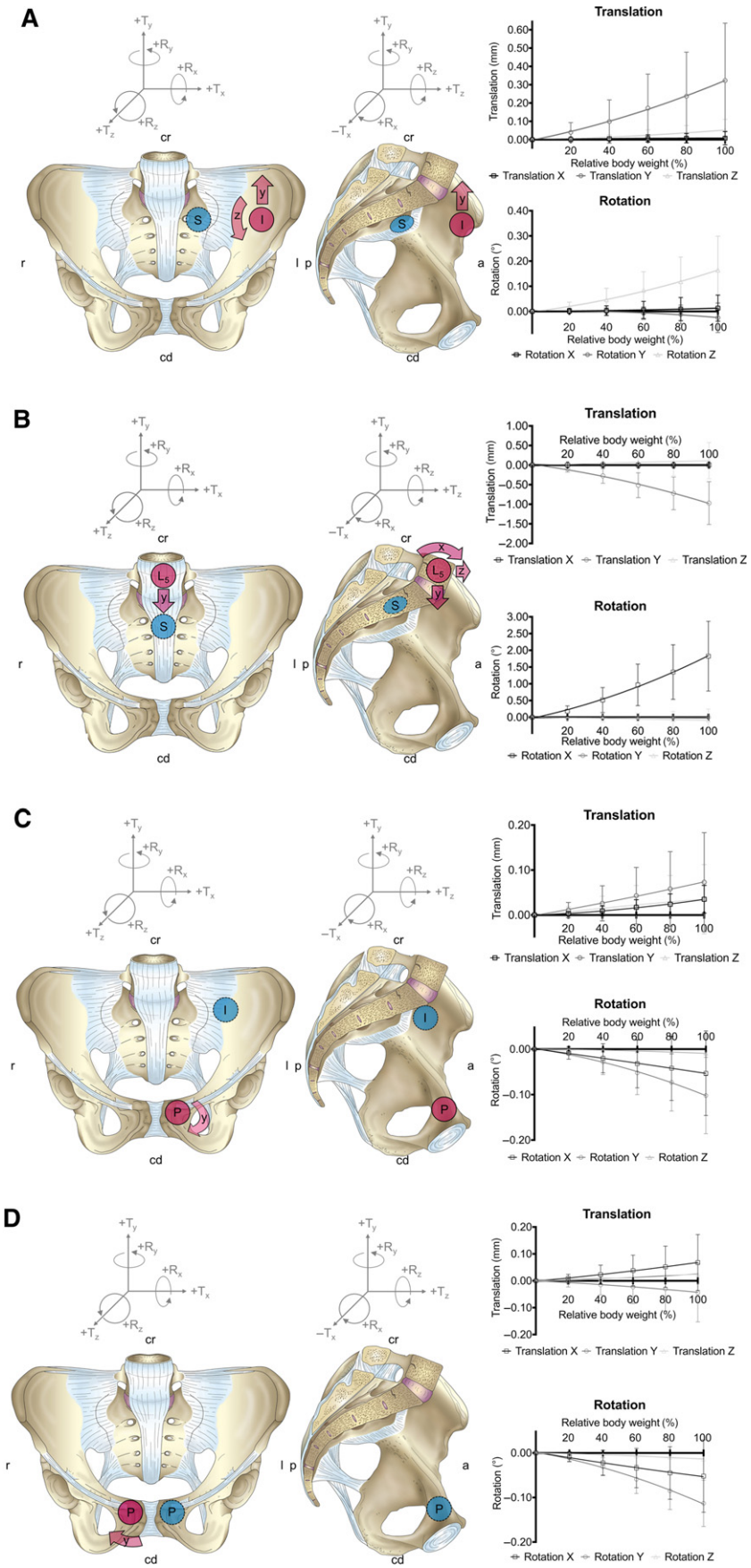

Figure 2 Movement patterns at the pelvic ring, relative to bodyweight. Left, anterior view, right, lateral view onto the right hemipelvis. The arrows indicate the movements between the segments to the one another, appreciating that there are no truly fixed points in the system. a, anterior; cd, caudal; cr, cranial; l, left; p, posterior; r, right. (A) Sacroiliac joint, movement of the sacrum (S) relative to the ilium (I). (B) Lumbosacral transition, movement of the fifth lumbar vertebra (L5) relative to the sacrum (S). (C) Innominate bone, movement of the pubis (P) relative to the ilium (I). (D) Pubic symphysis, movement of the left relative to the right superior pubic ramus.

Table 3 *In vivo* deformation data of the sacroiliac joints (SIJ) obtained from patients and patients with SIJ pain.

In vivo	Body position	Sample size	Age (years) mean ± SD, (range)	Measurement method	Rotation (degrees), mean ± SD, (range)			Translation (mm), mean ± SD, (range)			Accuracy (maximum possible error)
					x	*y*	*z*	*x*	*y*	*z*	
Egund et al. (1978)	Different positions	4 patients		Stereophotogrammetry	2.0						
Jacob & Kissling (1995)	Upright, lumbar anteflexion	24 participants	(20 to 50)	Stereophotogrammetry, k wires	1.1 ± 0.78	0.83 ± 0.81	0.59 ± 0.53	0.71 ± 0.75	0.45 ± 0.51	0.4 ± 0.45	0.34 mm
Kibsgård et al. (2012)	Standing	6 patients	38 (33 to 47)	Stereophotogrammetry	0.7*	0.2*	0.3*	0.5*	0.3*	0.4*	
Kibsgård et al. (2014a,b)	One-leg standing	11 patients	39 (29 to 27)	Stereophotogrammetry	0.1 ± 0.2	0.1 ± 0.2	0.3 ± 0.2	0.0 ± 0.2	0.0 ± 0.1	0.1 ± 0.1	0.1°, 0.1 mm
					(−0.7 to 0.9)	(−0.6 to 0.9)	(−0.2 to 1.0)	(−0.4 to 0.8)	(−0.2 to 0.5)	(−0.5 to 0.4)	
					0.5 ± 0.3			0.0 ± 0.1			
					(−0.7 to 1.3)			(−0.4 to 0.7)			
Kissling & Jacob (1996)	Standing	24 participants	(20 to 50)	Stereophotogrammetry, k wires	1.8 M, 1.9 F, 2.2 L, 2.1 R			0.7 M, 0.9 F, 0.9 bilateral			
					(0.7 to 4.4)			(0.3 to 1.6)			
Lavignolle et al. (1983)	Supine position	5 participants	<25	x-ray	(10.0 to 12.0)			6 mm			0.1 mm
Sturesson et al. (1989)	Supine to standing	25 patients	(18 to 45)	Stereophotogrammetry	−1.1 L, −1.2 R	0.1 L, 0.3 R	0.0 L, 0.1 R	0.4 L, 0.5 R			0.2°, 0.1 mm
					(−2.0 to 0.0)	(−0.1 to 1.2)	(−0.4 to 0.5)	(0.1 to 1.0)			
					2.5			0.7			
					(0.8 to 3.9)			(0.1 to 1.6)			
Sturesson et al. (1999)	Supine to standing	10 patients		Stereophotogrammetry	−1.1 median						0.3°
					(−2.4 to −0.4)						
Sturesson et al. (2000a,b)	Supine to standing	6 patients		Stereophotogrammetry	−1.1	0.5	0.3				0.2 to 0.4°, 0.2 mm
Weisl (1955)	Supine to standing	22 participants	(17 to 28)	*X*-ray	(−2.5 to 0.5)	(0.0 to 1.6)	(−1.0 to 0.2)				
					Total rotation 1.7 ± 0.86			5.6 ± 1.4			

F, female; L, left; M, male; R, right; SD, standard deviation.
*Values averaged from pre- and post-surgery.
Values are not given in the studies if they are not listed.

Table 4 *In vitro* deformation data of the sacroiliac joint.

Cadaveric	Body position	Sample size	Age (years) mean ± SD, (range)	Measurement method	Rotation (degrees), mean ± SD, (range)			Translation (mm), mean ± SD, (range)			Accuracy (maximum possible error)**
					x	*y*	*z*	*x*	*y*	*z*	
Frigerio et al. (1974)		1 pelvis (unclear if embalmed)	Not given	Stereophotogrammetry				−3.2 to 4.6			0.2 mm
Lindsey et al. (2014)	Standing	7 fresh lumbopelvises	59 ± 6.3	Axial (restrained) loading with 3.75–7.5 Nm maximum, metal markers	2.27 ± 1.35						
Miller et al. (1987)	Standing	8 fresh bilateral SIJ	59 to 74	Axial (restrained) loading 294 N, 42 Nm to S1 endplate	0.13 ± 0.23			0.8 to 2 mm			
Rothkötter & Berner (1988)	Standing	6 fresh pelvises	36.8 ± 15.1	Ventro-cranial (restrained) loading				0.4 ± 0.2 at 500 *N** 1.3 ± 1.0 at 2000 *N**			
Simonian et al. (1994a,b)	Standing	4 fresh lumbopelvises with femora	79 (76 to 96)	Axial (restrained) loading	0.5 ± 0.4			0.5 ± 0.4			
Vleeming et al. (1989)	Standing	4 embalmed lumbopelvises	77 (73 to 83)	Axial loading, restrained pelvis	(0.1 to 1.4)*						
Vleeming et al. (1992a)	Standing	6 embalmed lumbopelvises	(76 to 97)	Axial loading, restrained pelvis	(0.1 to 4.5)						
Vleeming et al. (1992b)	Standing	6 embalmed lumbopelvises	77 (73 to 83)	Axial loading, restrained pelvis	(0.0 to 4.0)						
Wang & Dumas (1998)	Standing	4 fresh female pelvises	Not given	Axial (constrained) loading of sacrum, maximum load 300–490 N	−1.2 at 60% bodyweight			0.9			0.04°, 0.01 mm

SD, standard deviation
*Estimated from the graphs
**Not given if not listed.

Posterior pelvis biomechanics revisited combining physiological loading with image correlation

The given experiments were the first attempt to identify the three-dimensional deformations occurring simultaneously at the SIJ and the surrounding osteoligamentous tissues, providing sound baseline data on its passive mobility. The setup allowed the application of optical image correlation to obtain highly accurate movements of the entire pelvis, with measurement errors lower than 0.02° or 0.01 mm, respectively – one magnitude lower than the threshold for identifying movements to be recognized. Moreover, using spherical joints in the L5 endplate and both hip joints allowed for a physiological load application similar to the situation *in vivo*. Moreover, an evaluation of the deformation related to both absolute loading (in N) and bodyweight (in %) (Wang & Dumas, 1998) provided realistic data which can be used for reference or numerical validation purposes. Previous SIJ biomechanical setups were commonly limited to the sacrum and ilium, either isolated from the remaining pelvis (Miller et al. 1987; Rothkötter & Berner, 1988; Bechtel, 2001) or in a uniaxial loading setup with one of the joint partners firmly attached (Simonian et al. 1994b; Wang & Dumas, 1998; Bruna-Rosso, 2014; Lindsey et al. 2014). This previous approach likely limited the interpretability of the movements, as, *in vivo*, both joint partners have a certain degree of freedom within the kinematic chain.

The SIJ and lumbosacral transition appear to have corresponding movements, limited to the sagittal plane in the functional pelvis

Studies examining the SIJ motion in living subjects (Lavignolle et al. 1983; Kissling & Jacob, 1996; Sturesson et al. 1999, 2000a; Kibsgård et al. 2014a; Table 3) tended to give higher motion values than cadaveric (Weisl, 1955; Kissling et al. 1990; Sturesson et al. 2000b; Kapandji, 2009; Table 4) and numerical studies (Ivanov et al. 2009; Sichting et al. 2014; Table 5), with rotations varying by up to two magnitudes. This might partially be related to vast interindividual variations, but more importantly a consequence of varying experimental setups, and the accuracy and the precision of the experiments. It has been stated previously that individuals with SIJ pain tend to have an increased range of motion (Snijders et al. 1993; Wang & Dumas, 1998; Mens et al. 2006). A brief literature review on existing *in vivo* studies on SIJ motion did not, however, provide clear evidence supporting this assumption (Table 3), or age (Brunner et al. 1991; Vleeming et al. 2012) or our findings in the present experiments with minute SIJ movements under physiological load.

Our results on SIJ flexion-extension rotation have been markedly different concerning translation compared with previous trials (Weisl, 1955; Egund et al. 1978; Miller et al. 1987; Sturesson et al. 1989, 1999, 2000a; Vleeming et al. 1989; Kissling et al. 1990; Simonian et al. 1994b; Jacob & Kissling, 1995; Kibsgård et al. 2012, 2014b). Especially, *in vitro* studies appear to overestimate the extent of motion (Vleeming et al. 1992a,b; Lindsey et al. 2014), potentially as a consequence of un-physiological loading or of limiting the multi-axial nutation of the SIJ to one or two planes with direct force application onto the sacral promontory. SIJ rotations beyond 2° are unlikely to appear under physiological conditions according to our given experiments. Our hypothesis that SIJ movement is markedly smaller than reported previously can be accepted regarding flexion-extension rotation if the lumbosacral transition is included in the loading scenario.

A number of studies have also found rotations in the vertical and the anterior-posterior axis (Sturesson et al. 1989, 2000a; Jacob & Kissling, 1995; Kibsgård et al. 2012, 2014a) or have reported multi-axial (helical) rotations (Kissling et al. 1990; Sturesson et al. 1999, 2000a; Kibsgård et al. 2012). Our results confirm the existence of a rotation in the SIJ in the anterior-posterior axis under L5 loading, but only minute vertical rotations. Of importance, the lumbosacral transition appears to have a significant involvement in

Table 5 *In-silico* deformation data of the sacroiliac joint.

In silico	Body position	Sample size	Age (years)	Measurement method	Rotation (degrees), mean ± SD, (range)			Translation (mm), mean ± SD, (range)		
					x	*y*	*z*	*x*	*y*	*z*
Bruna-Russo et al. (2016)				FE model, cadaveric study	1.1			0.225		
Ivanov et al. (2009)				FE model	0.45 at 400 N*			0.15*		
Sichting et al. (2014)				FE model	0.04		0.02			

SD, standard deviation.
*Estimated from the graphs.

movement patterns as seen in the SIJ under physiological loading, with flexion-extension rotations averaging 1.82° under 100% of the body loading. This was accompanied by an anterior-inferior translation of L5 relative to the sacrum, again larger than at the SIJ. These results provide evidence of the functional interrelation of the lumbosacrum and the SIJ, likely reinforced by the dense iliolumbar and sacroiliac ligaments (Hammer et al. 2009, 2010; Steinke et al. 2010).

The innominate bone and pubic symphysis appear to have minute but existing movements

Both the innominate bones and the pubic symphysis have shown small movements, composed mainly of rotations in the vertical axis. The superior pubic ramus rotated anteromedially relative to the ilium, and both pubic rami laterally, forming a counter movement. The observed motions may be responsible for the changes of the pelvic conjugate diameters (Klein, 1891; Weisl, 1955), and innominate bone movement appears to be the consequence of the long lever arms provided along the terminal line. Moreover, these minute movements may, to a certain degree, prevent stress fractures under peak loading.

The observed motions in the innominate bones and the pubic symphysis were accompanied by large variations, which may be related to sidedness and interindividual differences in the cadavers. Walheim & Selvik (1984) have determined *in vivo* global rotations on pubic symphysis mobility, accounting for 3° rotations and 2-mm translations, using roentgen stereophotogrammetric analysis, which are in the larger range of our combined pubic symphysis and innominate bone movements. Similar minute displacements were found in previous *in vitro* analyses (Giraldez-Sanchez et al. 2014; Gonzalvez et al. 2016).

Conclusions and clinical implications

The present study provides highly accurate three-dimensional insights into lumbopelvic ring motion, conforming to the natural condition under physiological loading via L5 and the acetabulum via ball joints, appreciating all degrees of freedom at the SIJ. Several clinical implications can be derived from the study, both relating to movement reduction of the posterior pelvis. It seems that the movement in the SIJ is limited, and this study supports earlier *in vivo* findings in this regard (Kibsgård et al. 2012, 2014b, 2017).

Existing surgical approaches to fuse the SIJ are to date based on the assumption that the SIJ movement itself is the main driver of the movement of the posterior pelvis (Ebraheim et al. 2010; Stark et al. 2011; Mason et al. 2013; Sturesson et al. 2016). Due to the small translations and rotations occurring at the SIJ, one may hypothesize that an isolated trans-sacroiliac fusion technique may reduce the small SIJ movement and consequently the compression forces of the SIJ by causing shifts in the peak loading cranially (L5) and laterally (innominate bones) of the implants (Sturesson et al. 1999). To date, sound anatomical and biomechanical evidence is lacking concerning pain originating from the SIJ exclusively, not from the adjacent segments (Szadek et al. 2010). The data presented here provide evidence of the lumbosacral transition being potentially of importance. This may not only have implications for the surgical treatment fusing the SIJ, but also for other methods of non-surgical treatment including pelvic orthoses, where movement patterns and their alterations have to date not been fully taken into account (Hammer et al. 2015; Soisson et al. 2015).

Limitations

A number of limitations apply for the given setup. First, the sample size is comparably small to investigate the effects of age, gender and sidedness. Secondly, the pelvises were freed from soft tissues such as muscles and pelvic viscera so that neither active nor passive mechanical properties are accounted for. This has partly been compensated by mimicking the main strains of erector spinae and the abdominal wall muscles, but is a simplification. Also, the old age of the cadavers limits the significance of the study, especially for younger populations, where different motion patterns might be possible.

Acknowledgements

We would like to express our gratitude to the body donors for the gift of body donation which made this research possible. Martin Heilemann, Robert Möbius and Toni Wendler helped with the data extraction and the MATLAB routine and the evaluations of the raw data. Robby McPhee helped with the drawings. Professor Gisela Sole proofread the article as a native speaker proficient in the field of biomechanics.

Author contributions

Concept/design: N.H., S.S., M.W. Data acquisition: N.H., S.S., M.W. Data analysis/interpretation: N.H., M.S., T.K., T.S. Critical revision and approval of article: N.H., M.S., T.K., S.K., R.G.

References

Al-Khayer A, Hegarty J, Hahn D, et al. (2008) Percutaneous sacroiliac joint arthrodesis: a novel technique. *J Spinal Disord Tech* **21**, 359–363.

Arumugam A, Milosavljevic S, Woodley S, et al. (2012) Effects of external pelvic compression on form closure, force closure, and neuromotor control of the lumbopelvic spine – a systematic review. *Man Ther* **17**, 275–284.

Bechtel R (2001) Physical characteristics of the axial interosseous ligament of the human sacroiliac joint. *Spine J* **1**, 255–259.

Biswas BK, Dey S, Biswas S, et al. (2016) Water-cooled radiofrequency neuroablation for sacroiliac joint dysfunctional pain. *J Anaesthesiol Clin Pharmacol* **32**, 525–527.

Bruna-Rosso C (2014). Étude bioméchanique par éléments finis de dispositifs d'arthrodèse de la jonction sacro-iliaque. Montral: Université De Montréal, École polytechnique de Montréal.

Bruna-Rosso C, Arnoux PJ, Bianco RJ, et al. (2016) Finite element analysis of sacroiliac joint fixation under compression loads. *Int J Spine Surg* **10**, 16.

Brunner C, Kissling R, Jacob HA (1991) The effects of morphology and histopathologic findings on the mobility of the sacroiliac joint. *Spine (Phila Pa 1976)* **16**, 1111–1117.

Buchowski JM, Kebaish KM, Sinkov V, et al. (2005) Functional and radiographic outcome of sacroiliac arthrodesis for the disorders of the sacroiliac joint. *Spine J* **5**, 520–528. discussion 529.

Cohen SP (2005) Sacroiliac joint pain: a comprehensive review of anatomy, diagnosis, and treatment. *Anest Analg* **101**, 1440–1453.

Cohen SP, Chen Y, Neufeld NJ (2013) Sacroiliac joint pain: a comprehensive review of epidemiology, diagnosis and treatment. *Expert Rev Neurother* **13**, 99–116.

Damen L, Spoor CW, Snijders CJ, et al. (2002) Does a pelvic belt influence sacroiliac joint laxity? *Clin Biomech* **17**, 495–498.

Duhon BS, Bitan F, Lockstadt H, et al. (2016) Triangular titanium implants for minimally invasive sacroiliac joint fusion: 2-year follow-up from a prospective multicenter trial. *Int J Spine Surg* **10**, 13.

Dussault RG, Kaplan PA, Anderson MW (2000) Fluoroscopy-guided sacroiliac joint injections. *Radiology* **214**, 273–277.

Ebraheim NA, Ramineni SK, Alla SR, et al. (2010) Sacroiliac joint fusion with fibular bone graft in patients with failed percutaneous iliosacral screw fixation. *J Trauma* **69**, 1226–1229.

Egund N, Jurik AG (2014) Anatomy and histology of the sacroiliac joints. *Semin Musculoskelet Radiol* **18**, 332–339.

Egund N, Olsson TH, Schmid H, et al. (1978) Movements in the sacroiliac joints demonstrated with roentgen stereophotogrammetry. *Acta Radiol Diagn (Stockh)* **19**, 833–846.

Fessler J (1894). Die Festigkeit der menschlichen Gelenke mit besonderer Berücksichtigung des Banapparates. Munich: Königlich Bayerische Ludwig-Maximilians-Universität.

Forst SL, Wheeler MT, Fortin JD, et al. (2006) The sacroiliac joint: anatomy, physiology and clinical significance. *Pain Physician* **9**, 61–67.

Fortin JD, Kissling RO, O'Connor BL, et al. (1999) Sacroiliac joint innervation and pain. *Am J Orthop (Belle Mead NJ)*, **28**, 687–690.

Frigerio NA, Stowe RR, Howe JW (1974) Movement of the sacroiliac joint. *Clin Orthop Relat Res* **(100)**, 370–377.

Fritz J, Henes JC, Thomas C, et al. (2008) Diagnostic and interventional MRI of the sacroiliac joints using a 1.5-T open-bore magnet: a one-stop-shopping approach. *AJR Am J Roentgenol* **191**, 1717–1724.

Giraldez-Sanchez MA, Lazaro-Gonzalvez A, Martinez-Reina J, et al. (2014) Percutaneous iliosacral fixation in external rotational pelvic fractures. A biomechanical analysis. *Injury* **46**, 327–332.

Gonzalvez AL, Reina JM, Luis PC, et al. (2016) Is cannulated-screw fixation an alternative to plate osteosynthesis in open book fractures? A biomechanical analysis. *Injury* **47**(Suppl 3), S72–S77.

Hammer N, Steinke H, Slowik V, et al. (2009) The sacrotuberous and the sacrospinous ligament – a virtual reconstruction. *Ann Anat* **191**, 417–425.

Hammer N, Steinke H, Böhme J, et al. (2010) Description of the iliolumbar ligament for computer-assisted reconstruction. *Ann Anat* **192**, 162–167.

Hammer N, Voigt C, Werner M, et al. (2014) Ethanol and formaldehyde fixation irreversibly alter bones' organic matrix. *J Mech Behav Biomed Mater* **29**, 252–258.

Hammer N, Möbius R, Schleifenbaum S, et al. (2015) Pelvic belt effects on health outcomes and functional parameters of patients with sacroiliac joint pain. *PLoS ONE* **10**, e0136375.

Höch A, Schimpf R, Hammer N, et al. (2017) Biomechanical analysis of stiffness and fracture displacement after using PMMA-augmented sacroiliac screw fixation for sacrum fractures. *Biomed Tech (Berl)* **62**, 421–428.

Ivanov AA, Kiapour A, Ebraheim NA, et al. (2009) Lumbar fusion leads to increases in angular motion and stress across sacroiliac joint: a finite element study. *Spine* **34**, E162–E169.

Jacob HA, Kissling RO (1995) The mobility of the sacroiliac joints in healthy volunteers between 20 and 50 years of age. *Clin Biomech* **10**, 352–361.

Jee H, Lee JH, Park KD, et al. (2014) Ultrasound-guided versus fluoroscopy-guided sacroiliac joint intra-articular injections in the noninflammatory sacroiliac joint dysfunction: a prospective, randomized, single-blinded study. *Arch Phys Med Rehabil* **95**, 330–337.

Kapandji IA (2009) *Funktionelle Anatomie der Gelenke: Schematisierte und kommentierte Zeichnungen zur menschlichen Biomechanik; Einbändige Ausgabe - Obere Extremität, Untere Extremität, Rumpf und Wirbelsäule*. Stuttgart: Thieme.

Kasliwal PJ, Kasliwal S (2016) Fluoroscopy-guided sacroiliac joint injection: description of a modified technique. *Pain Physician* **19**, E329–E338.

Khurana A, Guha AR, Mohanty K, et al. (2009) Percutaneous fusion of the sacroiliac joint with hollow modular anchorage screws: clinical and radiological outcome. *J Bone Joint Surg Br* **91**, 627–631.

Kibsgård TJ, Roise O, Stuge B, et al. (2012) Precision and accuracy measurement of radiostereometric analysis applied to movement of the sacroiliac joint. *Clin Orthop Relat Res* **470**, 3187–3194.

Kibsgård TJ, Roise O, Stuge B (2014a) Pelvic joint fusion in patients with severe pelvic girdle pain – a prospective single-subject research design study. *BMC Musculoskelet Disord* **15**, 85.

Kibsgård TJ, Roise O, Sturesson B, et al. (2014b) Radiosteriometric analysis of movement in the sacroiliac joint during a single-leg stance in patients with long-lasting pelvic girdle pain. *Clin Biomech (Bristol, Avon)* **29**, 406–411.

Kibsgård TJ, Röhrl SM, Røise O, et al. (2017) Movement of the sacroiliac joint during the Active Straight Leg Raise test in patients with long-lasting severe sacroiliac joint pain. *Clin Biomech (Bristol, Avon)* **47**, 40–45.

Kissling RO, Jacob HA (1996) The mobility of the sacroiliac joint in healthy subjects. *Bull Hosp Jt Dis* **54**, 158–164.

Kissling RO, Brunner C, Jacob HA (1990) Zur Beweglichkeit der Iliosakralgelenke in vitro. *Z Orthop Grenzgeb* **128**, 282–288.

Klein G (1891) Zur Mechanik des Ileosacralgelenkes. *Z Geburtshilfe Perinatol Gynäkol* **21**, 74–118.

Kube RA, Muir JM (2016) Sacroiliac joint fusion: one year clinical and radiographic results following minimally invasive sacroiliac joint fusion surgery. *Open Orthop J* **10**, 679–689.

Kurosawa D, Murakami E, Aizawa T (2016) Fluoroscopy-guided sacroiliac intraarticular injection via the middle portion of the joint. *Pain Med* **18**, 1642–1648.

Laplante BL, Ketchum JM, Saullo TR, et al. (2012) Multivariable analysis of the relationship between pain referral patterns and the source of chronic low back pain. *Pain Physician* **15**, 171–178.

Lavignolle B, Vital JM, Senegas J, et al. (1983) An approach to the functional anatomy of the sacroiliac joints in vivo. *Anat Clin* **5**, 169–176.

Le Blanche AF, Mabi C, Bigot JM, et al. (1996) The sacroiliac joint: anatomical study in the coronal plane and MR correlation. *Surg Radiol Anat* **18**, 215–220.

Lindsey DP, Perez-Orribo L, Rodriguez-Martinez N, et al. (2014) Evaluation of a minimally invasive procedure for sacroiliac joint fusion – an in vitro biomechanical analysis of initial and cycled properties. *Med Devices (Auckl)* **7**, 131–137.

Mason LW, Chopra I, Mohanty K (2013) The percutaneous stabilisation of the sacroiliac joint with hollow modular anchorage screws: a prospective outcome study. *Eur Spine J* **22**, 2325–2331.

Mens JMA, Damen L, Snijders CJ, et al. (2006) The mechanical effect of a pelvic belt in patients with pregnancy-related pelvic pain. *Clin Biomech* (Bristol, Avon) **21**, 122–127.

Miller AN, Routt ML Jr (2012) Variations in sacral morphology and implications for iliosacral screw fixation. *J Am Acad Orthop Surg* **20**, 8–16.

Miller JA, Schultz AB, Andersson GB (1987) Load-displacement behavior of sacroiliac joints. *J Orthop Res* **5**, 92–101.

Panjabi MM (1992a) The stabilizing system of the spine. Part I. Function, dysfunction, adaptation, and enhancement. *J Spinal Disord Tech* **5**, 383–9; discussion 397.

Panjabi MM (1992b) The stabilizing system of the spine. Part II. Neutral zone and instability hypothesis. *J Spinal Disord Tech* **5**, 390–6; discussion 397.

Robert R, Prat-Pradal D, Labat JJ, et al. (1998) Anatomic basis of chronic perineal pain: role of the pudendal nerve. *Surg Radiol Anat* **20**, 93–98.

Rothkötter HJ, Berner W (1988) Failure load and displacement of the human sacroiliac joint under in vitro loading. *Arch Orthop Trauma Surg* **107**, 283–287.

Schleifenbaum S, Prietzel T, Aust G, et al. (2016) Acellularization-induced changes in tensile properties are organ specific - an *in vitro* mechanical and structural analysis of porcine soft tissues. *PLoS ONE* **11**, e0151223.

Schwarzer AC, Aprill CN, Bogduk N (1995) The sacroiliac joint in chronic low back pain. *Spine* **20**, 31–37.

Sichting F, Rossol J, Soisson O, et al. (2014) Pelvic belt effects on sacroiliac joint ligaments: a computational approach to understand therapeutic effects of pelvic belts. *Pain Physician* **17**, 43–51.

Simonian PT, Routt ML, Harrington RM, et al. (1994a) Biomechanical simulation of the anteroposterior compression injury of the pelvis. An understanding of instability and fixation. *Clin Orthop Relat Res* **(309)**, 245–256.

Simonian PT, Routt ML, Harrington RM, et al. (1994b) Internal fixation of the unstable anterior pelvic ring: a biomechanical comparison of standard plating techniques and the retrograde medullary superior pubic ramus screw. *J Orthop Trauma* **8**, 476–482.

Snijders CJ, Vleeming A, Stoeckart R (1993) Transfer of lumbosacral load to iliac bones and legs Part 1: biomechanics of self-bracing of the sacroiliac joints and its significance for treatment and exercise. *Clin Biomech (Bristol, Avon)* **8**, 285–294.

Soisson O, Lube J, Germano A, et al. (2015) Pelvic belt effects on pelvic morphometry, muscle activity and body balance in patients with sacroiliac joint dysfunction. *PLoS ONE* **10**, e0116739.

Stark JGAF, Tania I, Idemmili C (2011) The history of sacroiliac joint arthrodesis: a critical review and introduction of a new technique. *Curr Orthop Pract* **22**, 545–557.

Steinke H, Hammer N, Slowik V, et al. (2010) Novel insights into the sacroiliac joint ligaments. *Spine* **35**, 257–263.

Steinke H, Lingslebe U, Böhme J, et al. (2012) Deformation behavior of the iliotibial tract under different states of fixation. *Med Eng Phys* **34**, 1221–1227.

Steinke H, Hammer N, Lingslebe U, et al. (2014) Ligament-induced sacral fractures of the pelvis are possible. *Clin Anat* **27**, 770–777.

Sturesson B, Selvik G, Uden A (1989) Movements of the sacroiliac joints. A roentgen stereophotogrammetric analysis. *Spine (Phila Pa 1976),*, **14**, 162–165.

Sturesson B, Udén A, Onsten I (1999) Can an external frame fixation reduce the movements in the sacroiliac joint? A radiostereometric analysis of 10 patients. *Acta Orthop Scand* **70**, 42–46.

Sturesson B, Udén A, Vleeming A (2000a) A radiostereometric analysis of movements of the sacroiliac joints during the standing hip flexion test. *Spine* **25**, 364–368.

Sturesson B, Udén A, Vleeming A (2000b) A radiostereometric analysis of the movements of the sacroiliac joints in the reciprocal straddle position. *Spine* **25**, 214–217.

Sturesson B, Kools D, Pflugmacher R, et al. (2016) Six-month outcomes from a randomized controlled trial of minimally invasive SI joint fusion with triangular titanium implants vs conservative management. *Eur Spine J* **26**, 708–719.

Szadek KM, van der Wurff P, van Tulder MW, et al. (2009) Diagnostic validity of criteria for sacroiliac joint pain: a systematic review. *J Pain* **10**, 354–368.

Szadek KM, Hoogland PVJM, Zuurmond WWA, et al. (2010) Possible nociceptive structures in the sacroiliac joint cartilage: an immunohistochemical study. *Clin Anat* **23**, 192–198.

Visser LH, Nijssen PG, Tijssen CC, et al. (2013) Sciatica-like symptoms and the sacroiliac joint: clinical features and differential diagnosis. *Eur Spine J* **22**, 1657–1664.

Vleeming A, Stoeckart R, Snijders CJ (1989) The sacrotuberous ligament; a conceptual approach to its dynamic role in stabilizing the sacroiliac joint. *Clin Biomech* **(Bristol, Avon) 4**, 201–203.

Vleeming A, Buyruk HM, Stoeckart R, et al. (1992a) An integrated therapy for peripartum pelvic instability: a study of the biomechanical effects of pelvic belts. *Am J Obstet Gynecol* **166**, 1243–1247.

Vleeming A, van Wingerden JP, Dijkstra PF, et al. (1992b) Mobility in the sacroiliac joints in the elderly: a kinematic and radiological study. *Clin Biomech* **(Bristol, Avon) 7**, 170–176.

Vleeming A, Pool-Goudzwaard AL, Hammudoghlu D, et al. (1996) The function of the long dorsal sacroiliac ligament: its implication for understanding low back pain. *Spine (Phila Pa 1976)*, **21**, 556–562.

Vleeming A, Schuenke MD, Masi AT, et al. (2012) The sacroiliac joint: an overview of its anatomy, function and potential clinical implications. *J Anat* **221**, 537–567.

Waisbrod H, Krainick JU, Gerbershagen HU (1987) Sacroiliac joint arthrodesis for chronic lower back pain. *Arch Orthop Trauma Surg* **106**, 238–240.

Walheim GG, Selvik G (1984) Mobility of the pubic symphysis. In vivo measurements with an electromechanic method and a roentgen stereophotogrammetric method. *Clin Orthop Relat Res* **(191)**, 129–135.

Wang M, Dumas GA (1998) Mechanical behavior of the female sacroiliac joint and influence of the anterior and posterior sacroiliac ligaments under sagittal loads. *Clin Biomech (Bristol, Avon)* **13**, 293–299.

Weisl H (1955) The movements of the sacroiliac joint. *Acta Anat (Basel)* **23**, 80–91.

Supporting Information

Additional Supporting Information may be found in the online version of this article:

Fig. S1. Movement patterns at the pelvic ring, absolute loading in steps between 0 and 500 N. Left: anterior view, right lateral view onto the right hemipelvis. The arrows indicate the movements between the segments one to the other, appreciating that there are no truly fixed points in the system. a, anterior; cd, caudal; cr, cranial; l, left; p, posterior; r, right.

Fig. S1A. Sacroiliac joint, movement of the sacrum (S) relative to the ilium (I).

Fig. S1B. Lumbosacral transition, movement of the fifth lumbar vertebra (L5) relative to the sacrum (S).

Fig. S1C. Innominate bone, movement of the pubis (P) relative to the ilium (I).

Fig. S1D. Pubic symphysis, movement of the left relative to the right superior pubic ramus.

Table S1. Relative movement.

Table S2. Absolute movement.

Table S3. Precision of the measurements.